

Intravenous Ascorbic Acid Infusion Improves Myocardial Perfusion Grade During Elective Percutaneous Coronary Intervention

Relationship With Oxidative Stress Markers

Stefania Basili, MD,† Gaetano Tanzilli, MD,* Enrico Mangieri, MD,*
Valeria Raparelli, MD,† Serena Di Santo, PhD,† Pasquale Pignatelli, MD,†
Francesco Violi, MD†

Rome, Italy

Objectives Our goal was to explore whether antioxidant vitamin C infusion is able to affect the microcirculation perfusion in patients undergoing elective percutaneous coronary intervention for stable angina.

Background Periprocedural myocardial injury in the setting of elective percutaneous coronary intervention is associated with increased risk of death, recurrent infarction, and revascularization at follow-up. Despite excellent epicardial blood flow, impaired microcirculatory reperfusion may persist and increases the risk of vascular recurrences. Post-percutaneous coronary intervention induced-oxidative stress is one of the potential mechanisms accounting for impaired perfusion.

Methods Fifty-six patients were enrolled in a prospective, single-center, randomized study comparing 1 g vitamin C infusion (16.6 mg/min, over 1 h before percutaneous coronary intervention) versus placebo.

Results At the baseline, Thrombolysis In Myocardial Infarction (TIMI) myocardial perfusion grade <2 was observed in 89% and in 86% of patients randomized to the placebo or vitamin C infusion group, respectively ($p > 0.05$). After percutaneous coronary intervention, these percentages decreased in the placebo group (32%) and in greater measure in the vitamin C group (4%, $p < 0.01$). Complete microcirculatory reperfusion (TIMI myocardial perfusion grade = 3) was achieved in 79% of the vitamin C-treated group compared with 39% of the placebo group ($p < 0.01$); 8-hydroxy-2-deoxyguanosine ($p < 0.002$) and 8-iso-prostaglandin $F_{2\alpha}$ ($p < 0.02$) plasma levels significantly increased in the placebo group while they were significantly reduced in the vitamin C-treated group ($p < 0.0001$). TIMI myocardial perfusion grade changes from the baseline showed significant correlation with 8-hydroxy-2-deoxyguanosine ($p < 0.006$) or 8-iso-prostaglandin $F_{2\alpha}$ ($p < 0.01$) plasma levels changes.

Conclusions In patients undergoing elective percutaneous coronary intervention, impaired microcirculatory reperfusion is improved by vitamin C infusion suggesting that oxidative stress is implicated in such a phenomenon. (J Am Coll Cardiol Intv 2010;3:221–9) © 2010 by the American College of Cardiology Foundation

Periprocedural myocardial injury in the setting of elective percutaneous coronary intervention (PCI) for stable angina is associated with increased risk of death, recurrent infarction, and revascularization at follow-up (1–3). Periprocedural myocardial injury may occur in up to 40% of otherwise successful and angiographically uncomplicated elective procedures (1–3). In these cases, myocardial injury takes place as a result of the impairment of downstream coronary microcirculation and is visualized with angiography as a persistence of abnormally slow myocardial blood flow or no-reflow in the microvasculature of the treated coronary artery (4,5).

Abbreviations and Acronyms

cTFC = corrected Thrombolysis In Myocardial Infarction frame count
cTpi = cardiac troponin I
F₂-IPs = F ₂ -isoprostanes
HR = heart rate
hs-CRP = high-sensitivity C-reactive protein
IQR = interquartile range
LAD = left anterior descending coronary artery
LVEF = left ventricular ejection fraction
MAP = mean arterial blood pressure
NO = nitric oxide
PCI = percutaneous coronary intervention
ROS = reactive oxygen species
SCr = serum creatinine levels
TMPG = Thrombolysis In Myocardial Infarction myocardial perfusion grade
8-iso-PGF_{2α} = 8-iso-prostaglandin F _{2α}
8-OHdG = 8-hydroxy-2-deoxyguanosine

To this end, the goal of reperfusion therapies has shifted to include reperfusion downstream at the level of the capillary bed. Thus, in a substudy of the Thrombolysis In Myocardial Infarction (TIMI) 10B trial, excellent epicardial blood flow assessed by use of corrected Thrombolysis In Myocardial Infarction frame count (cTFC) (6) and improved microvascular perfusion by use of the Thrombolysis In Myocardial Infarction myocardial perfusion grade (TMPG) (7) have been related to reduced in-hospital 30-day mortality. These indexes were also related to 2-year survival after administration of thrombolytics (8).

Multiple mechanisms have been suggested to contribute this impaired coronary flow, including local activation of the coagulation system and intracoronary thrombus formation, distal embolization of plaque and/or thrombus from the lesion site, vasoconstriction of the treated vessel and the distal microvasculature, and endothelial dysfunction (4,9).

Post-PCI induced-oxidative stress is another potential mechanism accounting for impaired perfusion. In previous studies, we and others have reported an increase in the concentration of F₂-isoprostanes (F₂-IPs), a stable end product of lipid peroxidation, in coronary sinus blood samples after PCI but not after diagnostic angiography (10,11).

These findings suggest that coronary angioplasty is associated with ischemia-related increase in oxidative stress. Vitamin C is an antioxidant molecule that quenches reactive oxygen species (ROS), inhibiting ROS-mediated nitric oxide (NO) inactivation (12–14).

This effect is likely to account for arterial dilation occurring in coronary and extracoronary districts after intravenous infusion of ascorbic acid (15–18). However, it has never been investigated whether vitamin C may influence the impairment of microcirculation perfusion occurring after PCI. We, therefore, performed an interventional study in patients undergoing elective PCI for stable angina to explore whether vitamin C infusion is able to affect the microcirculation perfusion in this subset of patients. Furthermore, we measured markers of oxidative stress to corroborate the antioxidant property of vitamin C in this experimental model.

Methods

Study participants. This was a prospective, single-center, placebo-controlled, randomized study. We studied 56 patients (47 men and 9 women, mean age 67 [50 to 84] years) with clinically stable class I or II effort angina pectoris according to the Canadian Cardiovascular Society criteria (19) and a single de novo lesion in a native coronary artery that was scheduled for elective PCI (Table 1). Angiographic inclusion criteria for interventional study was a target vessel reference diameter of 2.5 to 3.5 mm, all type A or type B lesions, as described by the American College of Cardiology/

Table 1. Clinical and Angiographic Characteristics of the Patients

	Placebo (n = 28)	p Value	Vitamin C (n = 28)
Age (yrs)	68 ± 9	>0.05	66 ± 8
Men	23 (82)	>0.05	24 (86)
CVD familiarity	17 (61)	>0.05	14 (50)
Hypertension	20 (71)	>0.05	20 (71)
Dyslipidemia	20 (71)	>0.05	19 (68)
Current smoker	13 (46)	>0.05	11 (39)
Diabetes mellitus	15 (54)	>0.05	18 (64)
Pharmacological therapy			
Oral hypoglycemic	12 (43)	>0.05	11 (39)
Insulin treatment	2 (7)	>0.05	3 (10)
Statins	19 (68)	>0.05	16 (57)
Nitrates	13 (46)	>0.05	16 (57)
ACE inhibitors	15 (54)	>0.05	12 (43)
Beta-blockers	9 (32)	>0.05	10 (36)
Calcium antagonists	7 (25)	>0.05	6 (21)
Target vessel			
Left anterior descending artery	18 (64)	>0.05	15 (54)
Left circumflex artery	3 (11)	>0.05	6 (21)
Right coronary artery	7 (25)	>0.05	7 (25)
Procedural data			
Diameter stenosis (%)	80.1 ± 9.7	>0.05	83.5 ± 11.5
Stent diameter (mm)	3.0 ± 0.39	>0.05	3.1 ± 0.37
Stent length (mm)	19.8 ± 7.1	>0.05	20.8 ± 7.5
Balloon pressure (atm)	16.5 ± 1.4	>0.05	16.9 ± 1.1

Values are mean ± SD or n (%).
ACE = angiotensin-converting enzyme; CVD = cardiovascular disease.

American Heart Association Task Force (20), a lesion length ≤ 33 mm, which would be covered with a single stent, diameter stenoses $\geq 70\%$ and $< 100\%$, and a TIMI flow grade > 1 .

Patients were selected among the 92 consecutive patients referred over an 8-month period (September 2007 and December 2008) to the Department of the Heart and Great Vessels "Attilio Reale," University of Rome "La Sapienza," Italy. Clinical exclusion criteria were contraindication to aspirin or clopidogrel ($n = 2$), previous myocardial infarction (13 patients), multivessel interventions ($n = 12$), graft vessel disease ($n = 5$), platelet count $< 100,000/\text{mm}^3$ ($n = 2$), and history of bleeding diathesis ($n = 2$). Informed consent was obtained from each participating subject, and the protocol was approved by the University of Rome "La Sapienza" Ethics Committee.

Study design. With the aim to evaluate the effect of vitamin C infusion on indexes of reperfusion (i.e., cTFC, TMPG) and inflammatory and oxidative stress markers after PCI, we planned an interventional study. All eligible patients were randomly assigned in a 1:1 manner to receive ascorbic acid solution (1 g of vitamin C Vita, [Sanofi-Aventis, Milan Italy] diluted in 250 ml of isotonic saline infused at 16.6 mg/min, 4.2 ml/min, over 1 h before PCI) or placebo (isotonic saline infused at 4.2 ml/min over 1 h before PCI).

All the participants were studied after a 12-h fast. Blood samples were collected at baseline (before the start of procedure) and after 60 min from the end of PCI to measure 8-iso-prostaglandin $F_{2\alpha}$ (8-iso-PGF $_{2\alpha}$) and 8-hydroxy-2-deoxyguanosine (8-OHdG), 2 blood markers of oxidative stress, and high-sensitivity C-reactive protein (hs-CRP) serum levels.

Serum cardiac-Troponin I (cTnI) was measured at baseline before the procedure, every 6 h over the next 2 days, and thereafter if these were abnormal values. cTnI levels were measured using an automated enzyme immuno assay system (Dimension RXL MAX, Siemens Healthcare Diagnostic, Eschborn, Germany) with the upper limit of normal being 0.05 ng/ml in our laboratory. Serum creatinine levels (SCr) were measured in the morning of the day before coronary angiography and of the day after PCI.

Left ventricular ejection fraction (LVEF) was calculated by the biplane Simpson's rule, as recommended by the American Society of Echocardiography at baseline and 72 h after PCI.

Primary and secondary end points. The primary end point was the assessment of cTFC and TMPG changes occurring after elective PCI. Secondary end points included: 1) the evaluation of the effect of vitamin C infusion on inflammatory and oxidative stress markers after PCI; 2) mean peak values of cTnI after the procedure; and 3) major adverse clinical events defined as a composite of death, acute myocardial infarction, and target vessel revascularization up to 6 months after interventions as assessed by telephone

contact or scheduled office visit by operators who were blinded to treatment allocation at the time of PCI and to any clinical, laboratory, and angiographic data.

Procedure of stent implantation. During the 24 h before the procedure and thereafter, all patients received aspirin (100 mg daily) and clopidogrel (loading dose of 300 mg, followed by 75 mg daily for at least 6 months). Preparation and percutaneous access were performed according to standard hospital procedures. After percutaneous access was obtained, an intravenous bolus of 5,000 U of unfractionated heparin was administered, with sufficient supplements (if necessary) to maintain an activated clotting time ≥ 250 s during intervention and for 2 h after stent implantation. A baseline angiography of the involved vessel was performed in at least 2 near orthogonal views that showed the target lesion free of foreshortening or vessel overlap, using a 6-F diagnostic catheter. The angiograms included at least 2 cm of catheter to allow for accurate quantitative coronary angiographic measurements. After identification of the target lesion that met all eligibility criteria, those patients who continued to meet eligibility criteria were randomized to placebo or ascorbic acid administration and received a unique study identification code.

The target lesion was crossed with a 0.014 exchange-length guidewire, and a single pre-dilation with an appropriately sized balloon was performed by inflating the balloon to the nominal pressure over a 15-s period. Within 1 min from balloon dilation, a sirolimus-eluting stent (Cypher, Cordis, Johnson & Johnson, Amersfoort, the Netherlands) was implanted. Stent deployment was achieved with high pressure balloon inflation (more than 15 atm) without any post-dilation. No direct stenting was performed. The procedure was considered successful when stent placement was associated with a residual stenosis $< 30\%$ and a TIMI flow grade 3.

Angiographic assessment. Angiograms recorded before and immediately after the procedure were assessed with the aid of the automated edge detection system (Centricity Cardiology CA 1000, GE Medical Systems, Milwaukee, Wisconsin). The quantitative measurements were performed on end-diastolic frames by 1 operator. The same projections were used at all time points. The central filled nontapered catheter tip was used for calibration. Early lumen gain was calculated as the difference between minimal lumen diameter at the end of the intervention and before balloon pre-dilation.

During angiography, imaging was recorded from the time of first injection of the coronary arteries until venous filling was observed and continued for at least 3 cardiac cycles at the washout phase. Epicardial coronary arteries were visualized in multiple views, including cranial and caudal angulations. Selective angiography was performed with an automatic injector (ACIST HD101, Eden Prairie, Minnesota), by using a total volume of 10 ml iopromide (Ultravist 370,

Schering AG, Berlin, Germany), at a rate of 2.0 ml/s for left coronary arteries, and a total volume of 8 ml iopromide at a rate of 1.0 ml/s for right coronary arteries, at 450 PSI. Baseline and post-interventional TIMI flow grade, cTFC, and TMPG were evaluated by an independent core laboratory (ROMA [Ricerche Orientate alla Malattia Aterosclerotica], Rome, Italy). The operators who performed the evaluation were unaware of the study protocol and of the patient's characteristics. Digital angiograms were analyzed off-line with the use of an automated edge detection system (Cardiovascular Medical System, MEDIS Imaging Systems, Leiden, the Netherlands).

TIMI flow grade. Angiographic TIMI flow grade of the diseased artery was estimated before and after completion of PCI according to 4 grades of flow, as previously described (21).

cTFC. The analysis of coronary flow was done according to the TIMI frame count method by Gibson et al. (21). The number of frames required for contrast to first reach standardized distal coronary landmarks was measured by the cine viewer frame counter. Cine film speed was 30 frames per second. Extrasystolic and post-extrasystolic beats were carefully excluded from analysis. The first frame used for TIMI counting was the first frame where the dye column extended more than 70% of the arterial lumen with antero-grade motion. The last frame counted was the first frame where the dye entered the distal landmark branch. The following distal landmarks were used for analysis: distal bifurcation of the left anterior descending coronary artery (LAD) known as moustache, pitch fork, or whale's tail; distal branch of the lateral left ventricular wall artery furthest from the coronary ostium for the left circumflex artery; first branch of posterolateral artery for the right coronary artery. The corrected TIMI frame count was calculated by dividing the LAD TIMI frame count by 1.7, and the mean value of both investigators' measurements was considered as the reference value for statistical analysis. Normal values were defined as follows: 36.2 ± 2.6 frames for the LAD; 22.2 ± 4.1 for the left circumflex artery; 20.4 ± 3.0 frames for the right coronary artery. Values above the normal frame count were considered suggestive for impairment of microcirculation.

TMPG. The TMPG (6) was used to assess the filling and clearance of contrast in the myocardium. TMPG0 was defined as no apparent tissue-level perfusion (no ground-glass appearance of blush or opacification of the myocardium) in the distribution of the culprit artery. TMPG1 indicated a presence of myocardial blush but no clearance from the microvasculature (blush or a stain present on the next injection). TMPG2 indicated that the blush cleared slowly (blush strongly persistent and diminished minimally or not at all during 3 cardiac cycles of the washout phase). TMPG-3 indicated that blush began to clear during washout (blush minimally persistent after 3 cardiac cycles of washout).

Analytical measurements. Blood samples were drawn from an antecubital vein with a 21-gauge needle and then mixed in a tube with 0.13 mmol/l sodium citrate (ratio 9:1). Samples were collected before and 60 min after the procedure.

Blood samples were immediately centrifuged at 2,000 rpm for 20 min at 4°C, and the supernatant was collected and stored at -80°C until measurement. Plasma levels of 8-OHdG (Quantikine R&D Systems, Minneapolis, Minnesota) and hsCRP (Tema Ricerca Srl, Bologna, Italy) were measured with a commercial immunoassay. Intra-assay and interassay coefficients of variation were 2.1% and 4.5% for 8-OHdG, and 8.3% and 7.8% for hsCRP. The analytical measurements were performed blinded to any clinical and angiographic data.

8-iso-PGF_{2alpha}. NaOH (10 N) was added to the samples and heat at 45°C for 2 h, then were added with 100 μl of concentrated HCl (12 N) per 500 μl of hydrolyzed sample. The samples were centrifuged for 5 min at 14,000 rpm in a microcentrifuge. The levels of 8-iso-PGF_{2alpha} in clear supernatant were measured with a commercial immunoassay (Assay the Designs, Ann Arbor, Michigan). Intra-assay and interassay coefficients of variation were 5.7% and 5.8%.

Statistical analysis. Differences between percentages were assessed by chi-square test or Fisher exact test. Student unpaired *t* test and Pearson product-moment correlation analysis were used for normally distributed continuous variables. Appropriate nonparametric tests (Mann-Whitney *U* test and Spearman rank correlation test) were employed for all the other variables. Multiple linear regression analyses were performed to further quantify the relationship between clinical and biochemical variables. The differences between baseline and post-treatment values were analyzed with the Wilcoxon signed rank test.

A sample size of 20 patients undergoing vitamin C infusion provided the intervention study with 80% power to detect a 50% improvement in TMPG with respect to the placebo group. This minimum sample size could be increased to 28 patients in order to keep the degrees of freedom for the assessment of treatment effect in the statistical analysis at the required level. Sample size calculation was performed using the software nQuery Advisor, version 5.0 (Statistical Solutions, Saugus, Massachusetts). Data are presented as mean (1 SD) or as median and interquartile range (IQR) (25th, 75th percentile). Only *p* values <0.05 were regarded as statistically significant. All tests were 2-tailed, and analyses were performed using a computer software package (Statistica version 7, Stat-Soft Inc., Tulsa, Oklahoma, or Statistical Package for the Social Sciences, version 16.0, SPSS Inc., Chicago, Illinois).

Results

The enrolled patients completed all phases of the study. No side effects were observed during or after ascorbic acid or

placebo infusion. Table 1 shows baseline demographic and clinical characteristics of patients according to randomization at the infusion treatment. Age, sex, risk factor distribution, and concomitant pharmacological treatment did not differ between the groups (Table 1).

Forty-five patients (22 in the vitamin C and 23 in the placebo group) experienced angina during stent deployment; of those, 12 patients (6 for each group) showed significant ST-segment downsloping during balloon inflation. The time duration of balloon occlusion did not differ between treated patients and control subjects (22 ± 9 s vs. 23 ± 9 s, respectively, $p = \text{NS}$). cTPI was always within the upper limits of normal values in both groups. The median absolute increase in serum troponin level was similar between control patients and the ascorbic acid group (median [IQR] 0.027 [0.05 to 0.032] vs. 0.008 [0.02 to 0.013] ng/ml, respectively, $p = 0.0832$).

The SCr levels increased from (median [IQR]) 0.97 (0.78 to 1.15) mg/dl to 1.26 (1.02 to 1.33) mg/dl ($p < 0.0001$) in the placebo group within 24 h of contrast administration but decreased from 0.90 (0.89 to 1.08) to 0.86 (0.75 to 0.93) ($p < 0.001$) in patients receiving ascorbic acid. After 24 h of the procedure end, the 2 groups significantly differed in SCr changes from the baseline ($p < 0.001$).

Baseline mean values of LVEF were similar in both the vitamin C and control groups ($52.3 \pm 4.3\%$ vs. $53.7\% \pm 3.9\%$, $p = \text{NS}$). After intervention, LVEF improved in both groups with a higher increase in vitamin C-treated patients compared with the placebo group ($58.3 \pm 2.9\%$ vs. $54.1 \pm 4.7\%$, respectively, $p < 0.03$). Vitamin C-treated patients showed a greater improvement of LVEF after the procedure compared with that observed in the control group ($p < 0.01$).

Baseline mean values of heart rate (HR) and mean arterial blood pressure (MAP) were overlapping between the 2 treatment groups (vitamin C vs. control group; HR 72.4 ± 8.9 vs. 69.5 ± 10.6 , $p = \text{NS}$; MAP 104 ± 17.1 vs. 105.2 ± 17.2 , $p = \text{NS}$). Patients receiving ascorbic acid infusion showed similar changes in HR (72.9 ± 12 vs. 71.7 ± 11.9 , $p = \text{NS}$) and MAP (102 ± 20.7 vs. 103.9 ± 19.4 , $p = \text{NS}$) compared with those receiving placebo infusion.

Angiographic and interventional data. The implantation of a single stent was successful in all patients with complete covering of the vessel lesion length and without quantitative coronary angiographic residual stenosis within the stent. Furthermore, angiographic images obtained after stent deployment did not show signs of endothelial dissection in the areas proximal or distal to the stent struts. There were no differences in early lumen gain and final diameter stenosis between the 2 groups (Table 1).

Reperfusion indexes. The cTFCs before stent implantation were similar between the 2 groups (placebo vs. vitamin C infusion: 40.2 ± 9.9 frames/s vs. 36.1 ± 8.9 frames/s, $p > 0.05$). Seventy-one percent of patients allocated to the placebo group and 86% of those assigned to the vitamin C group had

cTFC ranging from 20 to 40 frames/s ($p > 0.05$); the remaining patients ($n = 8$ in the placebo group and $n = 4$ in the vitamin C group) had cTFC more than 40 frames/s ($p > 0.05$). After PCI, both groups (placebo 30.3 ± 8.0 frames, $p < 0.0001$; vitamin C infusion group 21.3 ± 5.2 frames, $p < 0.0001$) showed a statistically significant reduction in cTFC compared with baseline values; nevertheless, at the end of infusion, cTFC was significantly lower in the vitamin C group (median change -41%) compared with the placebo group (median changes -23% , $p < 0.0001$) (Fig. 1A). Interestingly, 1 patient (4%) in the placebo group and 16 (57%) patients in

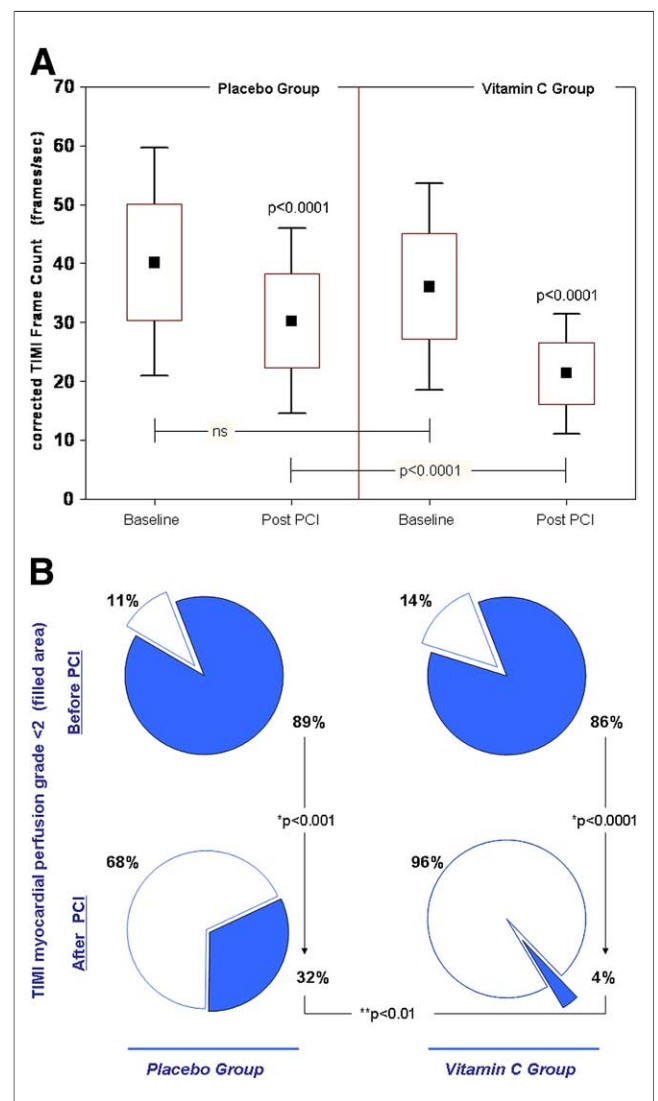


Figure 1. cTFC and TMPG Before and After Placebo or Vitamin C Infusion

Corrected Thrombolysis In Myocardial Infarction frame count (cTFC) (A) and Thrombolysis In Myocardial Infarction myocardial perfusion grade (TMPG) (B) before and after placebo or vitamin C infusion. *McNemar chi-square; **Fisher exact test. Triangles in B contain numbers of each TMPG grade (0, 1, 2, 3) before and after percutaneous coronary intervention (PCI) in each group. TIMI = Thrombolysis In Myocardial Infarction.

vitamin C group reached lower-risk (≤ 20 frames/s) cTFC class ($p < 0.0001$).

At the baseline, TMPG < 2 was observed in 89% and in 86% patients randomized to the placebo or vitamin C infusion group, respectively ($p > 0.05$). After PCI, these percentages decreased in the placebo group (32%) and in greater measure in the vitamin C group (4%) ($p < 0.01$) (Fig. 1B).

A normal perfusion (TMPG = 3) was detected in 79% ($n = 22$) of patients allocated to ascorbic acid compared with 39% ($n = 11$) of those allocated to placebo ($p < 0.01$). In the overall population, TMPG and cTFC changes from the baseline showed a significant correlation ($R_s = 0.60, p < 0.05$).

Indexes of oxidative stress and inflammation. At the baseline, the 2 intervention groups did not differ in serum values of 8-OHdG (vitamin C group 3.7 ± 1.4 ng/ml vs. placebo group 3.4 ± 1.1 ng/ml, $p = 0.3733$), of 8-iso-PGF_{2alpha} (median [IQR] 142.5 [85.5 to 187.5] pg/ml vs. 126.0 [85.0 to 170.0] pg/ml, $p = 0.4172$), and hs-CRP (1.3 ± 0.9 mg/l vs. 1.5 ± 0.8 mg/l, $p = 0.5397$). Thus, before the start of the interventional procedure, 8-OHdG and 8-iso-PGF_{2alpha} plasma levels were significantly correlated in the 58 studied patients ($R_s = 0.56, p < 0.0001$). The hs-CRP

did not show a significant correlation with either index of oxidative stress (data not shown).

Sixty minutes after balloon inflation 8-OHdG (4.2 ± 1.1 ng/ml, $p < 0.002$) and 8-iso-PGF_{2alpha} ($161.5 [117.5 to 190.0]$ pg/ml, $p < 0.02$) plasma levels significantly increased in the placebo group; on the contrary, the 2 indexes of oxidative stress significantly decreased in the vitamin C-treated group (8-OHdG 2.6 ± 1.1 ng/ml, $p < 0.0001$; 8-iso-PGF_{2alpha} 50 [20.7 to 102.5] pg/ml, $p < 0.0001$). Accordingly, as shown in Figures 2A and 2B, 60 min after balloon inflation the 2 groups significantly differed in serum values of 8-OHdG ($p < 0.001$) and of 8-iso-PGF_{2alpha} ($p < 0.0001$). After 60 min of the interventional procedure, 8-OHdG and 8-iso-PGF_{2alpha} plasma levels were still significantly correlated in the overall population ($R_s = 0.49, p < 0.0002$).

Bivariate correlations. In all studied patients, cTFC changes from the baseline did not show a significant correlation with 8-OHdG ($R_s = -0.22, p = 0.0972$) or 8-iso-PGF_{2alpha} ($R_s = -0.25, p = 0.0604$) plasma level changes from baseline. In contrast, TMPG changes from the baseline showed a significant correlation with 8-OHdG ($R_s = -0.36, p <$

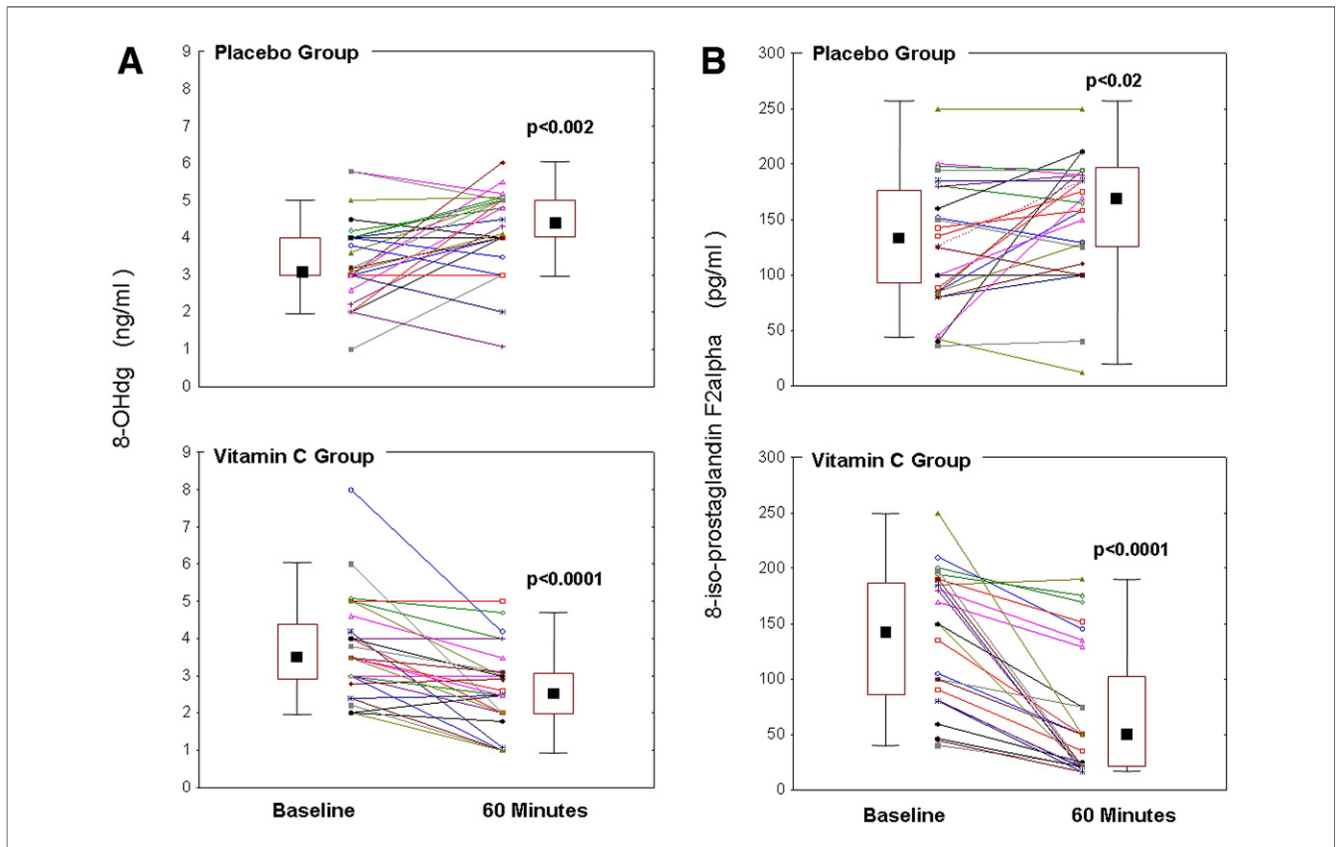


Figure 2. 8-OHdG and 8-iso-PGF_{2alpha} Before and After Placebo or Vitamin C Infusion

8-hydroxy-2-deoxyguanosine (8-OHdG) (A) and 8-iso-prostaglandin F_{2alpha} (8-iso-PGF_{2alpha}) (B) in the placebo group (upper panel) and in the vitamin C group (lower panel). The differences between baseline and post-treatment values were analyzed with the Wilcoxon signed rank test.

0.006) or 8-iso-PGF_{2α} (R_s = -0.35, p < 0.01) plasma level changes from baseline.

Adverse cardiac events. There were no adverse events during hospitalization in both groups. None of the patients died during the follow-up. No thrombosis-related events occurred after a mean time of 15 ± 4.5 months after interventions. The cumulative event rate was 7.2%: 3 patients (5.3%) in the placebo group and 1 patient (3.5%) in the vitamin C group needed restenosis-related target vessel revascularization.

Discussion

The present study provides evidence that vitamin C infusion improves myocardium reperfusion via inhibition of oxidative stress in patients undergoing PCI. Impaired microcirculatory perfusion is usually detected in patients undergoing PCI. According to other studies showing reduced TMPG ranging from 52% to 94% (22–26), our patients at baseline showed TMPG <2 in 87.5% of the recruited patients. This could be dependent on the coexistence of risk factors such as diabetes and hypertension, which could hamper microvascular perfusion (27,28).

PCI restoration of epicardial flow does not necessarily lead to restoration of tissue level or microvascular perfusion. Thus, previous studies showed that achievement of TMPG ≥2 can be observed in about 65% to 85% of all patients undergoing PCI for acute coronary syndrome; this percentage fell to 25% to 60% considering only the subgroup of patients achieving optimal microvascular reperfusion (TMPG = 3) (22–26). A similar reperfusion rate was observed in our placebo-allocated group (39%) while the vitamin C-allocated group showed a much higher reperfusion rate (79%) suggesting that vitamin C infusion enhances coronary perfusion at a microcirculatory level.

A potential role of oxidative stress in impairing myocardium reperfusion has been suggested by the elevation of several markers of oxidative stress occurring after PCI likely as a consequence of the ischemia-reperfusion phenomenon (11,29–31). More recently, an inverse association between myeloperoxidase, a reactive oxidant species-generating enzyme, and TMPG was observed, but a cause-effect relationship was not determined (32). Our data extend these findings as we show that oxidative stress is implicated in impairing microcirculatory flow. Thus, infusion of vitamin C, which is known to quench oxygen radicals, was associated with improvement of microcirculatory perfusion coincidentally with inhibition of oxidative stress.

The fact that vitamin C infusion blunted in vivo the increase of 2 markers of oxidative stress, namely 8-OHdG and F₂-IPs, is consistent with previous studies showing that such a pharmacological route exerts an antioxidant effect (13,33–36). This is likely dependent on the fact that vitamin C infusion is associated with supra-physiologic blood concentrations (i.e., millimolar), which are necessary to scav-

enge superoxide radicals and to eventually exert an antioxidant property (13,33–36). This pharmacological property has been suggested to account for the vasodilating property of vitamin C that has been observed in either extracoronary or coronary macro-circulation (17,37–39). Notably, Kaufmann et al. (40) found that intravenous vitamin C is also able to improve microcirculatory flow as shown by the fact that it increased coronary flow reserve in smokers. This effect could be achieved via vitamin C interference with NO bioactivity/biosynthesis. Thus, vitamin C stabilizes BH4 levels by regenerating BH4 from its oxidized form (34,41–43). As oxidative inactivation of BH4 impairs endothelial NO synthase (44–46), BH4 stabilization by vitamin C could restore endothelial NO synthase activity and NO biosynthesis (47,48). Also, vitamin C inhibits nicotinamide adenine dinucleotide phosphate oxidase (13,49–52), the main cellular source of superoxide radicals (53), and scavenges superoxide radicals, 2 effects that result in reduced NO inactivation by ROS.

Inhibition of F₂-IPs could represent, per se, another putative mechanism that, however, has been recently questioned (54,55). Thus, F₂-IPs exert a vasoconstriction effect on the arterial wall (56–58) and could be responsible for post-PCI no-reflow phenomenon as they sharply increase after PCI (11,12,29). A recent study, however, showed that after PCI the local (coronary) blood concentration was too low to exert a coronary vasoconstriction effect (59). Based on these data, the decrease of F₂-IPs by vitamin C should be regarded, at the moment, as a mere epiphenomenon of the antioxidant property of vitamin C.

This study has implications and limitations. An interesting finding of the study was the higher increase of LVEF in the vitamin C-treated group compared with the placebo group. Even if this effect on ventricular function could have a beneficial impact in the clinical history of vitamin C-treated patients, the very few vascular outcomes do not attribute a clinical relevance to this potentially interesting data. Further study is, therefore, necessary to see if vitamin C infusion is actually associated with improved clinical outcome in patients undergoing PCI.

Even if the increase of microvascular reperfusion was coincident with oxidative stress reduction, a cause-effect relationship cannot be established as no biological markers of arterial dilation were investigated.

Vitamin C has a short half-life (60); therefore, reperfusion amelioration would probably be a consequence of a short-term effect on arterial dilation; other mechanisms, such as a decrease of micro-embolization, which would require a prolonged effect, are unlikely but cannot be excluded.

Conclusions

We show that in patients undergoing elective PCI, impaired microcirculatory reperfusion is improved by vitamin C

infusion. This suggests that oxidative stress is implicated in such a phenomenon and provides a rationale to test the clinical efficacy of vitamin C infusion in this setting.

Reprint requests and correspondence: Prof. Francesco Violi, Prima Clinica Medica, Viale del Policlinico 155, Roma 00161, Italy. E-mail: francesco.violi@uniroma1.it.

REFERENCES

- Brener SJ, Ellis SG, Schneider J, Topol EJ. Frequency and long-term impact of myonecrosis after coronary stenting. *Eur Heart J* 2002;23:869-76.
- Prasad A, Singh M, Lerman A, Lennon RJ, Holmes DR Jr., Rihal CS. Isolated elevation in troponin T after percutaneous coronary intervention is associated with higher long-term mortality. *J Am Coll Cardiol* 2006;48:1765-70.
- Nienhuis MB, Ottervanger JP, Bilo HJ, Dikkeschei BD, Zijlstra F. Prognostic value of troponin after elective percutaneous coronary intervention: a meta-analysis. *Catheter Cardiovasc Interv* 2008;71:318-24.
- Herrmann J. Peri-procedural myocardial injury: 2005 update. *Eur Heart J* 2005;26:2493-519.
- Taylor AJ, Al-Saadi N, Abdel-Aty H, et al. Elective percutaneous coronary intervention immediately impairs resting microvascular perfusion assessed by cardiac magnetic resonance imaging. *Am Heart J* 2006;151:891.e1-7.
- Gibson CM, Cannon CP, Daley WL, et al. The TIMI frame count: a quantitative method of assessing coronary artery flow. *Circulation* 1996;93:879-88.
- Gibson CM, Cannon CP, Murphy SA, et al. Relationship of TIMI myocardial perfusion grade to mortality after administration of thrombolytic drugs. *Circulation* 2000;101:125-30.
- Gibson CM, Cannon CP, Murphy SA, Marble SJ, Barron HV, Braunwald E. TIMI Study Group. Relationship of the TIMI myocardial perfusion grades, flow grades, frame count, and percutaneous coronary intervention to long-term outcomes after thrombolytic administration in acute myocardial infarction. *Circulation* 2002;105:1909-13.
- Gregorini L, Marco J, Farah B, et al. Effects of selective α_1 - and α_2 -adrenergic blockade on coronary flow reserve after coronary stenting. *Circulation* 2002;106:2901-7.
- Reilly MP, Delanty N, Roy L, et al. Increased formation of the isoprostanes IPF2 α -I and 8-epi-prostaglandin F2 α in acute coronary angioplasty: evidence for oxidant stress during coronary reperfusion in humans. *Circulation* 1997;96:3314-20.
- Iuliano L, Praticò D, Greco C, et al. Angioplasty increases coronary sinus F2-isoprostane formation: evidence for in vivo oxidative stress during PTCA. *J Am Coll Cardiol* 2001;37:76-80.
- Taddei S, Virdis A, Ghiadoni L, Magagna A, Salvetti A. Vitamin C improves endothelium-dependent vasodilation by restoring nitric oxide activity in essential hypertension. *Circulation* 1998;97:2222-9.
- Jackson TS, Xu A, Vita JA, Keaney JF Jr. Ascorbate prevents the interaction of superoxide and nitric oxide only at very high physiological concentrations. *Circ Res* 1998;83:916-22.
- Hornig B, Arakawa A, Kohler C, Drexler H. Vitamin C improves endothelial function of conduit arteries in patients with chronic heart failure. *Circulation* 1998;97:363-8.
- Carr AC, Zhu BZ, Frei B. Potential antiatherogenic mechanisms of ascorbate (vitamin C) and alpha-tocopherol (vitamin E). *Circ Res* 2000;87:349-54.
- Cangemi R, Angelico F, Loffredo L, et al. Oxidative stress-mediated arterial dysfunction in patients with metabolic syndrome: effect of ascorbic acid. *Free Radic Biol Med* 2007;43:853-9.
- Tousoulis D, Xenakis C, Tentolouris C, et al. Effects of vitamin C on intracoronary L-arginine dependent coronary vasodilatation in patients with stable angina. *Heart* 2005;91:1319-23.
- Hamabe A, Takase B, Uehata A, Kurita A, Ohsuzu F, Tamai S. Impaired endothelium-dependent vasodilation in the brachial artery in variant angina pectoris and the effect of intravenous administration of vitamin C. *Am J Cardiol* 2001;87:1154-9.
- Canadian Cardiovascular Society. Canadian Cardiovascular Society grading of angina pectoris. Available at: http://www.ccs.ca/download_position_statements/Grading%20of%20Angina.pdf. Accessed November 22, 2006.
- Smith SC Jr., Feldman TE, Hirshfeld JW Jr., et al. ACC/AHA/SCAI 2005 guideline update for percutaneous coronary intervention—summary article: a report of the American College of Cardiology/American Heart Association Task Force on Practice Guidelines (ACC/AHA/SCAI Writing Committee to Update the 2001 Guidelines for Percutaneous Coronary Intervention). *J Am Coll Cardiol* 2006;47:216-35.
- Gibson CM, Murphy SA, Rizzo MJ, et al. Relationship between TIMI frame count and clinical outcomes after thrombolytic administration. Thrombolysis In Myocardial Infarction (TIMI) Study Group. *Circulation* 1999;99:1945-50.
- Maioli M, Bellandi F, Leoncini M, Toso A, Dabizzi RP. Randomized early versus late abciximab in acute myocardial infarction treated with primary coronary intervention (RELAX-AMI trial). *J Am Coll Cardiol* 2007;49:1517-24.
- Gibson CM, Murphy SA, Marble SJ, et al. Relationship of creatine kinase-myocardial band release to Thrombolysis in Myocardial Infarction perfusion grade after intracoronary stent placement: an ESPRIT substudy. *Am Heart J* 2002;143:106-10.
- Lee DP, Herity NA, Hiatt BL, et al. Tirofiban Given in the Emergency Room before Primary Angioplasty. Adjunctive platelet glycoprotein IIb/IIIa receptor inhibition with tirofiban before primary angioplasty improves angiographic outcomes: results of the Tirofiban Given in the Emergency Room before Primary Angioplasty (TIGER-PA) pilot trial. *Circulation* 2003;107:1497-501.
- Chevalier B, Gilard M, Lang I, et al. Systematic primary aspiration in acute myocardial percutaneous intervention: a multicentre randomised controlled trial of the export aspiration catheter. *EuroIntervention* 2008;4:222-8.
- McLaughlin MG, Stone GW, Aymong E, et al. Controlled Abciximab and Device Investigation to Lower Late Angioplasty Complications trial. Prognostic utility of comparative methods for assessment of ST-segment resolution after primary angioplasty for acute myocardial infarction: the Controlled Abciximab and Device Investigation to Lower Late Angioplasty Complications (CADILLAC) trial. *J Am Coll Cardiol* 2004;44:1215-23.
- Prasad A, Stone GW, Stuckey TD, et al. Impact of diabetes mellitus on myocardial perfusion after primary angioplasty in patients with acute myocardial infarction. *J Am Coll Cardiol* 2005;45:508-14.
- Camicci PG, Crea F. Coronary microvascular dysfunction. *N Engl J Med* 2007;356:830-40.
- Berg K, Wiseth R, Bjerve K, et al. Oxidative stress and myocardial damage during elective percutaneous coronary interventions and coronary angiography. A comparison of blood-borne isoprostane and troponin release. *Free Radic Res* 2004;38:517-25.
- Inoue T, Kato T, Hikichi Y, et al. Stent-induced neutrophil activation is associated with an oxidative burst in the inflammatory process, leading to neointimal thickening. *Thromb Haemost* 2006;95:43-8.
- Tsimikas S, Lau HK, Han KR, et al. Percutaneous coronary intervention results in acute increases in oxidized phospholipids and lipoprotein(a): short-term and long-term immunologic responses to oxidized low-density lipoprotein. *Circulation* 2004;109:3164-70.
- Funayama H, Ishikawa SE, Sugawara Y, Kubo N, Momomura SI, Kawakami M. Myeloperoxidase may contribute to the no-reflow phenomenon in patients with acute myocardial infarction. *Int J Cardiol* 2009; Jan 10 [E-pub ahead of print].
- Baker TA, Milstien S, Katusic ZS. Effect of vitamin C on the availability of tetrahydrobiopterin in human endothelial cells. *J Cardiovasc Pharmacol* 2001;37:333-8.
- Kuzkaya N, Weissmann N, Harrison DG, Dikalov S. Interactions of peroxynitrite, tetrahydrobiopterin, ascorbic acid and thiols: implications for uncoupling endothelial nitric oxide synthase. *J Biol Chem* 2003;278:22546-54.

35. Jourdain D, Jourdain FL, Kutchukian PS, Musah RA, Wink DA, Grisham MB. Reaction of superoxide and nitric oxide with peroxynitrite: implications for peroxynitrite-mediated oxidation reactions in vivo. *J Biol Chem* 2001;276:28799-805.
36. Carr A, Frei B. The role of natural antioxidants in preserving the biological activity of endothelium-derived nitric oxide. *Free Radic Biol Med* 2000;28:1806-14.
37. Higa OH, Parra ER, Ab'Saber AM, Farhat C, Higa R, Capelozzi VL. Protective effects of ascorbic acid pretreatment in a rat model of intestinal ischemia-reperfusion injury: a histomorphometric study. *Clinics* 2007;62:315-20.
38. Mack WJ, Mocco J, Ducruet AF, et al. A cerebroprotective dose of intravenous citrate/sorbitol-stabilized dehydroascorbic acid is correlated with increased cerebral ascorbic acid and inhibited lipid peroxidation after murine reperfused stroke. *Neurosurgery* 2006;59:383-8.
39. Solzbach U, Hornig B, Jeserich M, Just H. Vitamin C improves endothelial dysfunction of epicardial coronary arteries in hypertensive patients. *Circulation* 1997;96:1513-9.
40. Kaufmann PA, Gnechchi-Ruscione T, di Terlizzi M, Schäfers KP, Lüscher TF, Camici PG. Coronary heart disease in smokers: vitamin C restores coronary microcirculatory function. *Circulation* 2000;102:1233-8.
41. Marui N, Offermann MK, Swerlick R, et al. Vascular cell-adhesion molecule-1 (Vcam-1) gene-transcription and expression are regulated through an antioxidant sensitive mechanism in human vascular endothelial-cells. *J Clin Invest* 1993;92:1866-74.
42. Heller R, Unbehau A, Schellenberg B, Mayer B, Werner-Felmayer G, Werner ER. L-ascorbic acid potentiates endothelial nitric oxide synthesis via a chemical stabilization of tetrahydrobiopterin. *J Biol Chem* 2001;276:40-7.
43. Huang A, Vita JA, Venema RC, Keaney JF. Ascorbic acid enhances endothelial nitric-oxide synthase activity by increasing intracellular tetrahydrobiopterin. *J Biol Chem* 2000;275:17399-406.
44. Hong HJ, Hsiao G, Cheng TH, Yen MH. Supplementation with tetrahydrobiopterin suppresses the development of hypertension in spontaneously hypertensive rats. *Hypertension* 2001;38:1044-8.
45. Landmesser U, Dikalov S, Price SR, et al. Oxidation of tetrahydrobiopterin leads to uncoupling of endothelial cell nitric oxide synthase in hypertension. *J Clin Invest* 2003;111:1201-9.
46. Shinozaki K, Kashiwagi A, Nishio Y, et al. Abnormal biopterin metabolism is a major cause of impaired endothelium-dependent relaxation through nitric oxide/ O_2^- imbalance in insulin-resistant rat aorta. *Diabetes* 1999;48:2437-45.
47. D'Uscio LV, Milstien S, Richardson D, Smith L, Katusic ZS. Long-term vitamin C treatment increases vascular tetrahydrobiopterin levels and nitric oxide synthase activity. *Circ Res* 2003;92:88-95.
48. Smith AR, Visioli F, Hagen TM. Vitamin C matters: increased oxidative stress in cultured human aortic endothelial cells without supplemental ascorbic acid. *FASEB J* 2002;16:1102-4.
49. May JM. How does ascorbic acid prevent endothelial dysfunction? *Free Radic Biol Med* 2000;28:1421-9.
50. Wu F, Schuster DP, Tymi K, Wilson JX. Ascorbate inhibits NADPH oxidase subunit p47phox expression in microvascular endothelial cells. *Free Radic Biol Med* 2007;42:124-31.
51. Papparella I, Ceolotto G, Berto L, et al. Vitamin C prevents zidovudine induced NAD(P)H oxidase activation and hypertension in the rat. *Cardiovasc Res* 2007;73:432-8.
52. Chen X, Touyz RM, Park JB, Schiffrin EL. Antioxidant effects of vitamins C and E are associated with altered activation of vascular NADPH oxidase and superoxide dismutase in stroke-prone SHR. *Hypertension* 2001;38:606-11.
53. Mohazzab KM, Kaminski PM, Wolin MS. NADH oxidoreductase is a major source of superoxide anion in bovine coronary-artery endothelium. *Am J Physiol* 1994;266:H2568-72.
54. Delanty N, Reilly MP, Pratico D, et al. 8-epi PGF2 alpha generation during coronary reperfusion. A potential quantitative marker of oxidant stress in vivo. *Circulation* 1997;95:2492-9.
55. Kijima Y, Hashimura K, Matsu-ura Y, et al. Transcardiac 8-isoprostaglandin F (2 alpha) generation from acute myocardial infarction heart: insight into abrupt reperfusion and oxidant stress. *Prostaglandins Leukot Essent Fatty Acids* 2001;64:161-6.
56. Möbert J, Becker BF, Zahler S, Gerlach E. Hemodynamic effects of isoprostanes (8-iso-prostaglandin F2alpha and E2) in isolated guinea pig hearts. *J Cardiovasc Pharmacol* 1997;29:789-94.
57. Kromer BM, Tippins JR. Coronary artery constriction by the isoprostane 8-epi prostaglandin F2 alpha. *Br J Pharmacol* 1996;119:1276-80.
58. Cracowski JL, Marliere S, Bessard G. Vasomotor effects and pathophysiological relevance of F(2)-isoprostane formation in vascular diseases. *J Am Coll Cardiol* 2002;39:554-5.
59. Greaves K, Dixon SR, Coker IO, et al. Influence of isoprostane F2alpha-III on reflow after myocardial infarction. *Eur Heart J* 2004;25:847-53.
60. Padayatty SJ, Sun H, Wang Y, et al. Vitamin C pharmacokinetics: implications for oral and intravenous use. *Ann Intern Med* 2004;140:533-7.

Key Words: corrected TIMI frame count ■ myocardial perfusion ■ oxidative stress ■ percutaneous coronary intervention ■ periprocedural myocardial injury ■ TIMI myocardial perfusion grade.